

RADIOLOGY REPORT

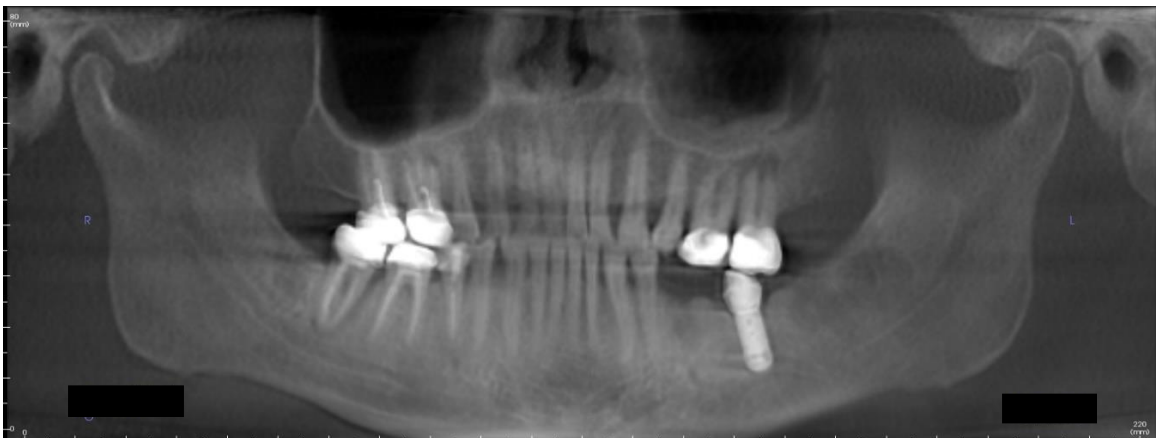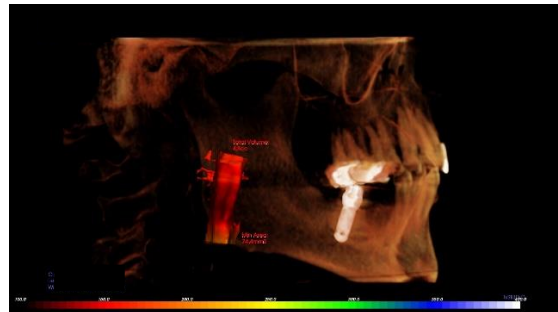
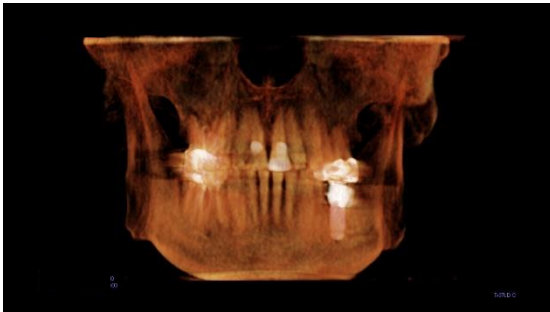
PATIENT NAME: AAAAAAAAAA DDDDDDDDDDD
DATE OF BIRTH: 05/18/41
DATE OF EXAMINATION: June 14, 2033
REFERRING DOCTOR: Dr. GGGGGGGGGG RTRRRRRR

TYPE OF EXAMINATION: Computed tomography utilizing volumetric data acquisition in order to minimize radiation dose to the patient.

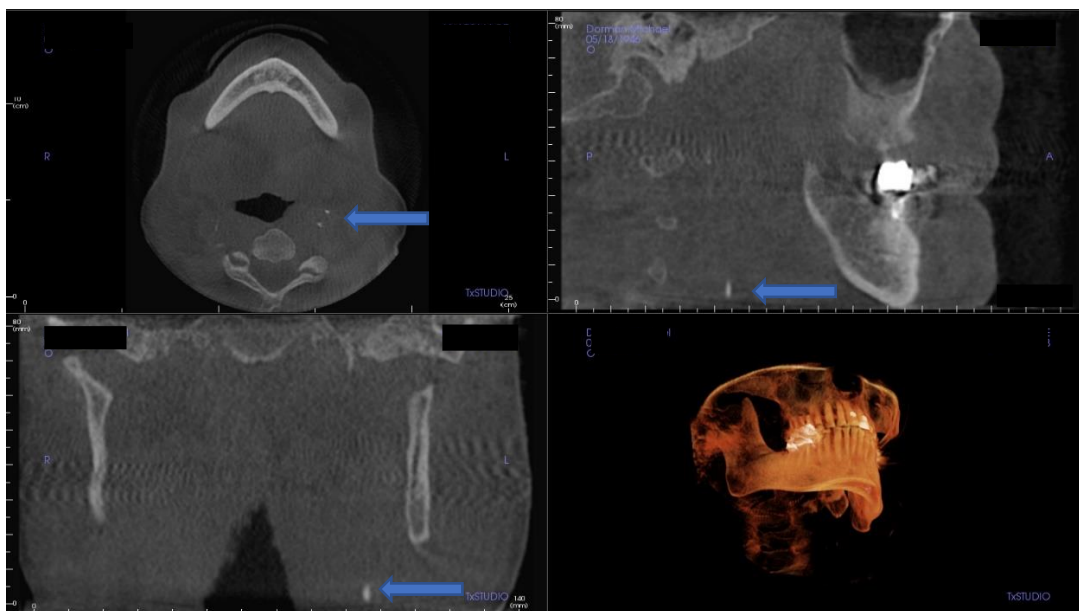
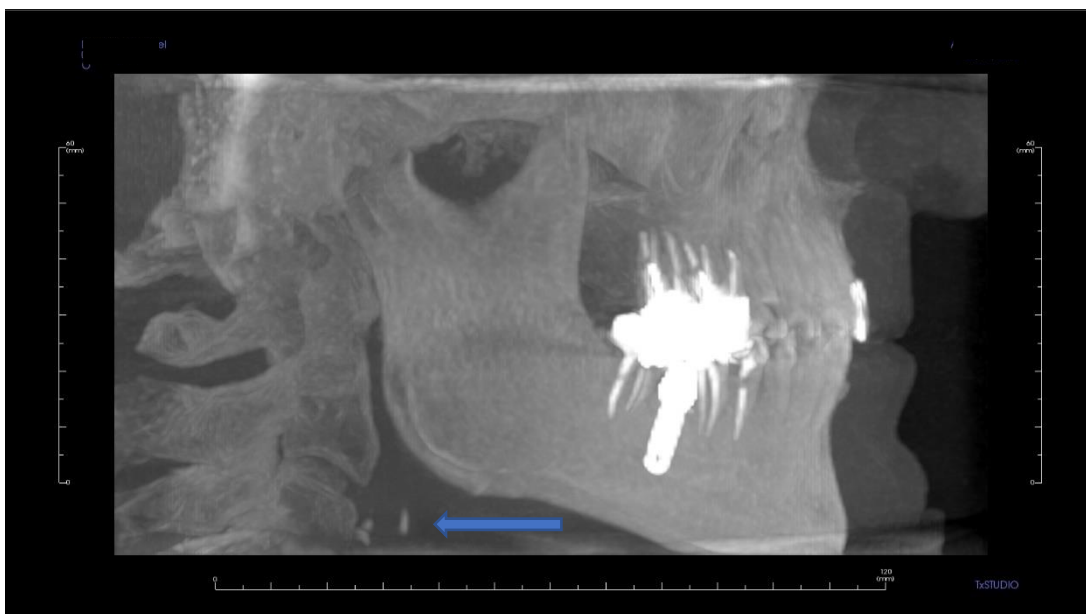
DIAGNOSTIC IMPRESSION

The TMJ condylar heads are mildly posteriorly placed within the glenoid fossa. Opacities noted region C3 are indicative of external carotid artery calcifications. Patient should be advised to inform their medical healthcare provider for definitive diagnosis. Increased mucosal thickening is noted in the left maxillary sinus adjacent to area tooth #15. Radiolucency is noted periapical region tooth #15. A periapical radiolucency is noted area tooth #31. The remainder of the scan is essentially unremarkable. Study should be correlated with clinical examination, medical history and patient dialogue.

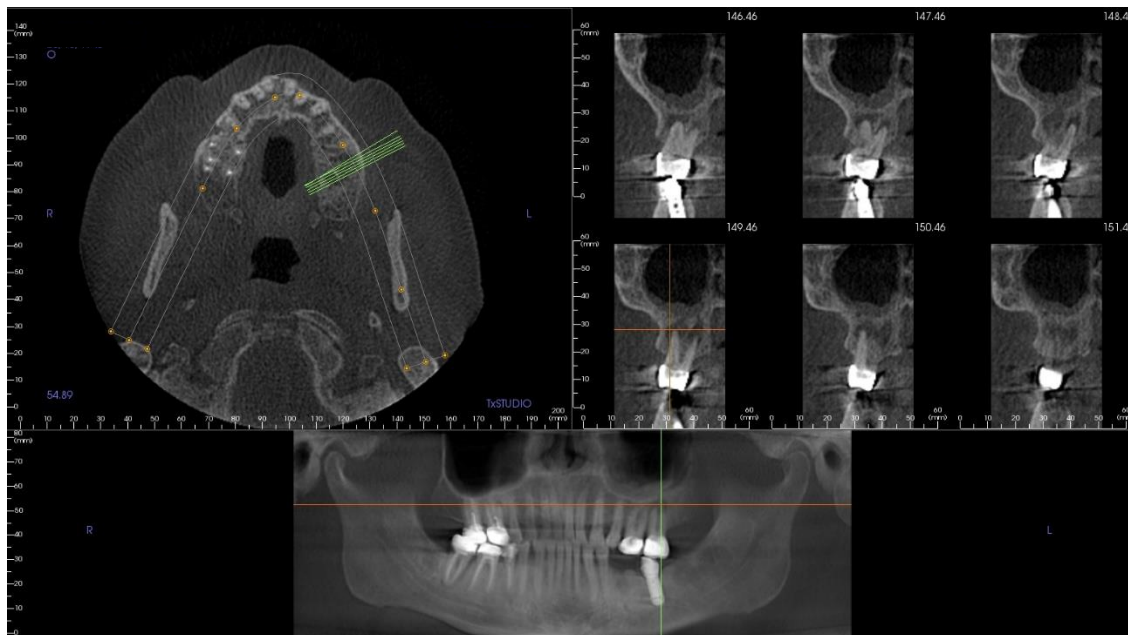
DETAILED ANALYSIS: The three-dimensionally rendered images demonstrate the relative osseous relationship of the mandible to the maxilla and the maxilla to the craniofacial base. No remarkable osseous dysmorphism is noted. The visualized portions of the upper airway appear relatively unobstructed. The panoramic image depicts a partial overview of the anatomic structures within the oral and maxillofacial complex:



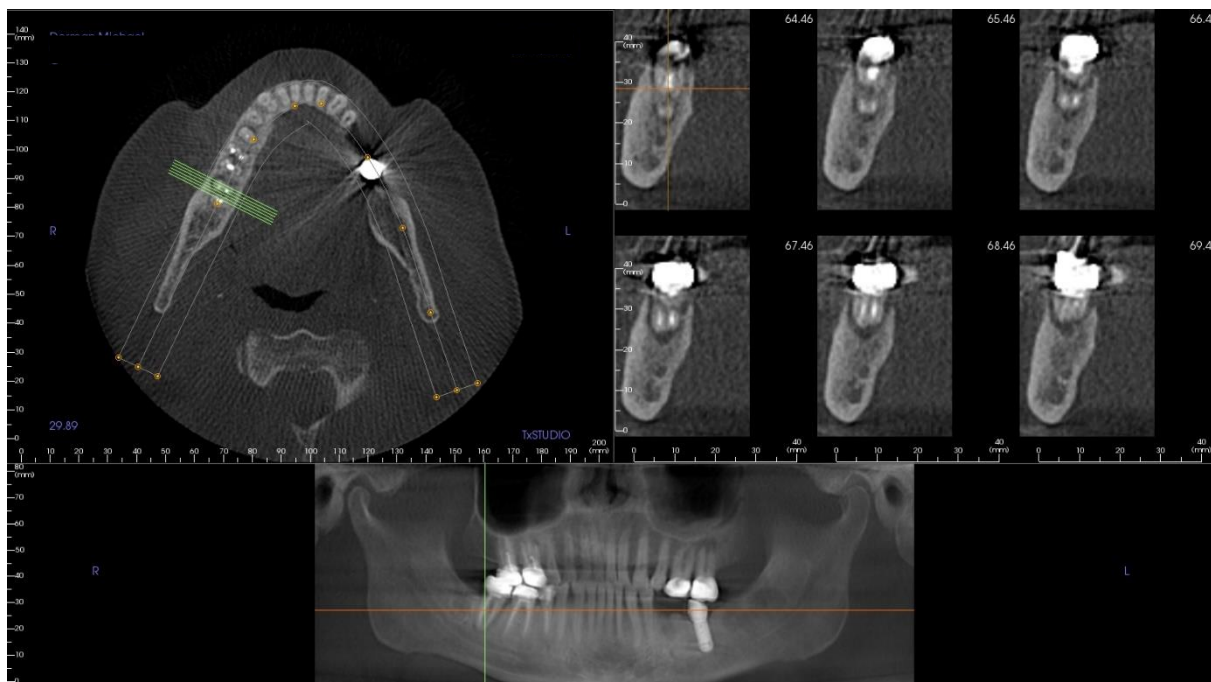
The multiplanar images depict an undistorted view of the osseous anatomy. Opacities noted region C3 are indicative of external carotid artery calcifications. Patient should be advised to inform their medical healthcare provider for definitive diagnosis:



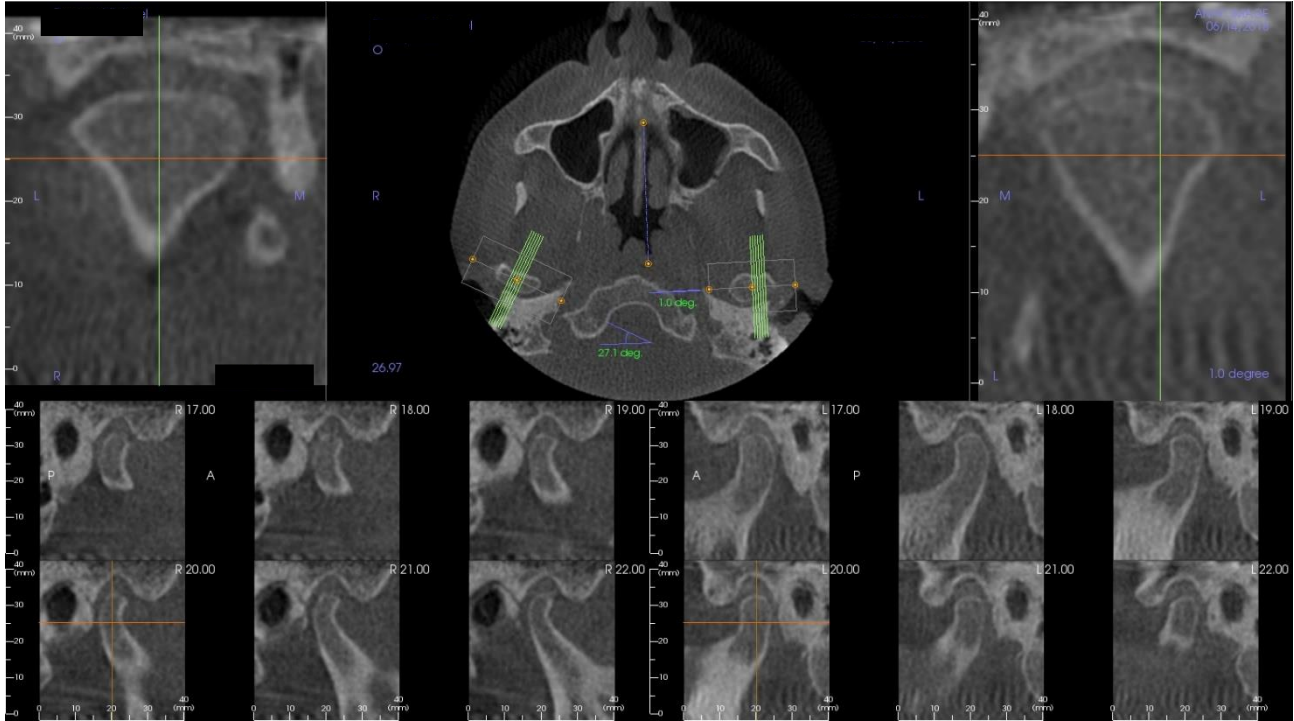
The imaged region of the spine demonstrates no indications of active pathology. Increased mucosal thickening is noted in the left maxillary sinus adjacent to area tooth #15. Radiolucency is noted periapical region tooth #15:



A periapical radiolucency is noted area tooth #31:



An evaluation of the visualized components of the right and left temporomandibular joints was performed. The cortical outline of the TMJ condylar heads is within normal limits. The condylar heads are mildly posteriorly placed within the glenoid fossa. The temporal component is unremarkable bilaterally:



Please contact me directly at (312) 933-6666 or contact@MonahanRadiology.com if you have any questions. Thank you for referring to my practice.

Richard Monahan, DDS, MS, JD
Diplomate, American Board of Oral & Maxillofacial Radiology

June 126, 2034
Date of Report