

RADIOLOGY REPORT

PATIENT NAME: EEEEEEEEEEE HHHHHHHHHHHHH

DATE OF BIRTH: 08/24/4444

DATE OF EXAMINATION: July 5, 2033

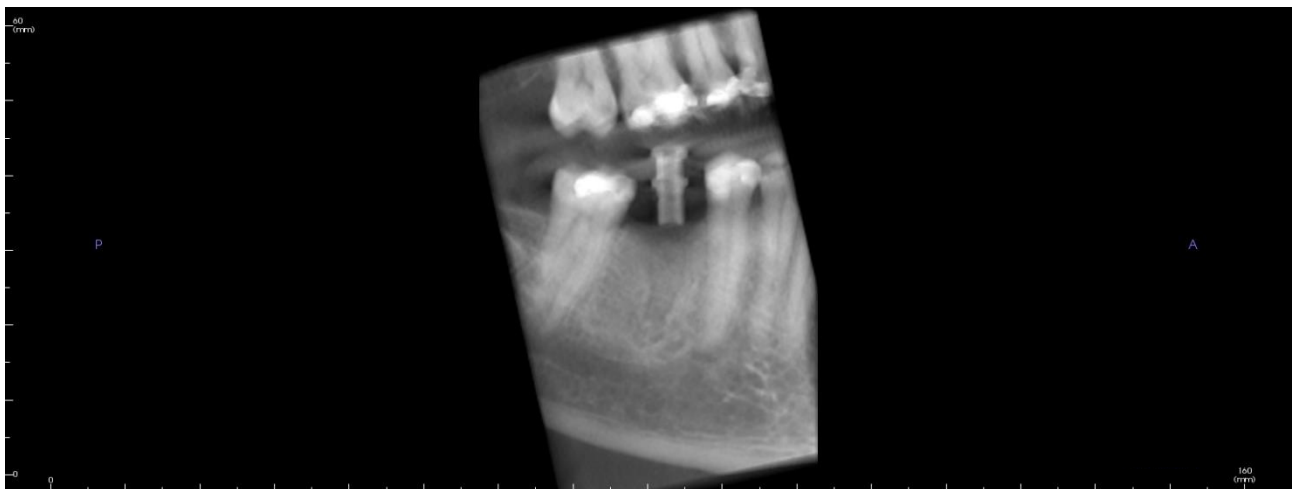REFERRING DOCTOR: Dr. YYYYYY RRRRRRR

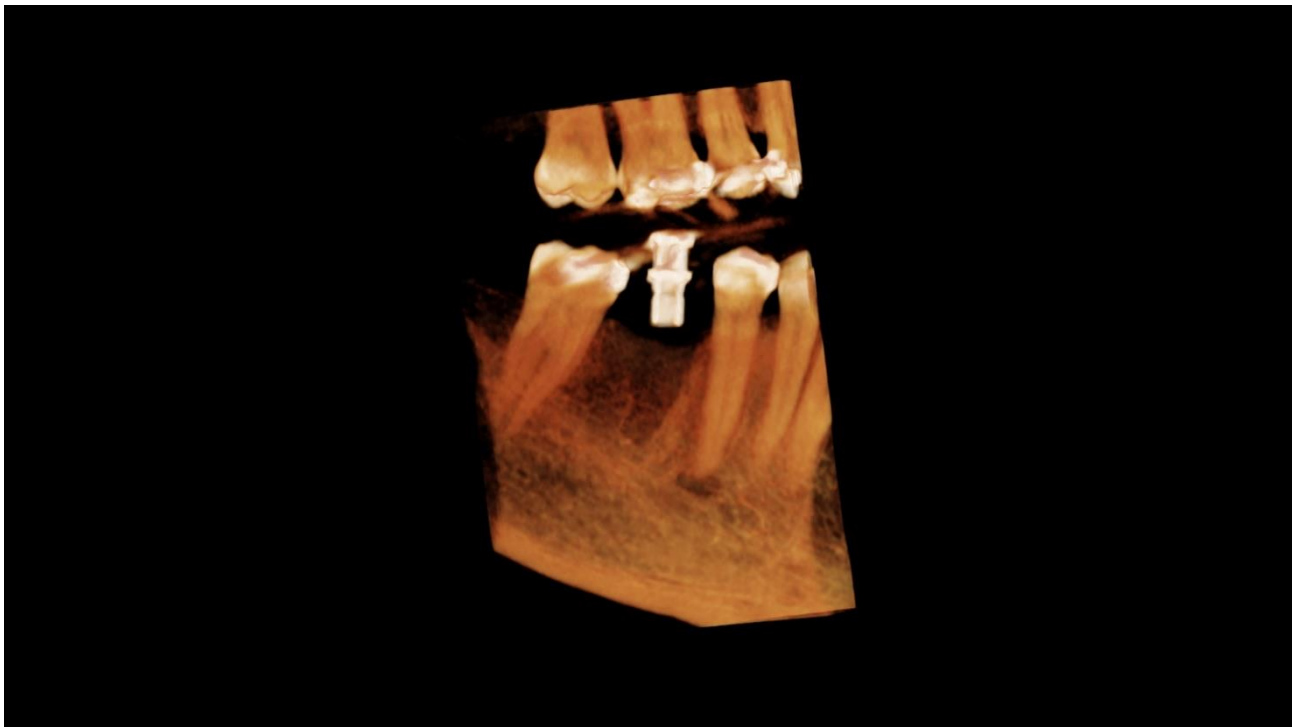
TYPE OF EXAMINATION: computed tomography utilizing volumetric data acquisition in order to minimize the radiation dose to the patient.

DIAGNOSTIC IMPRESSION

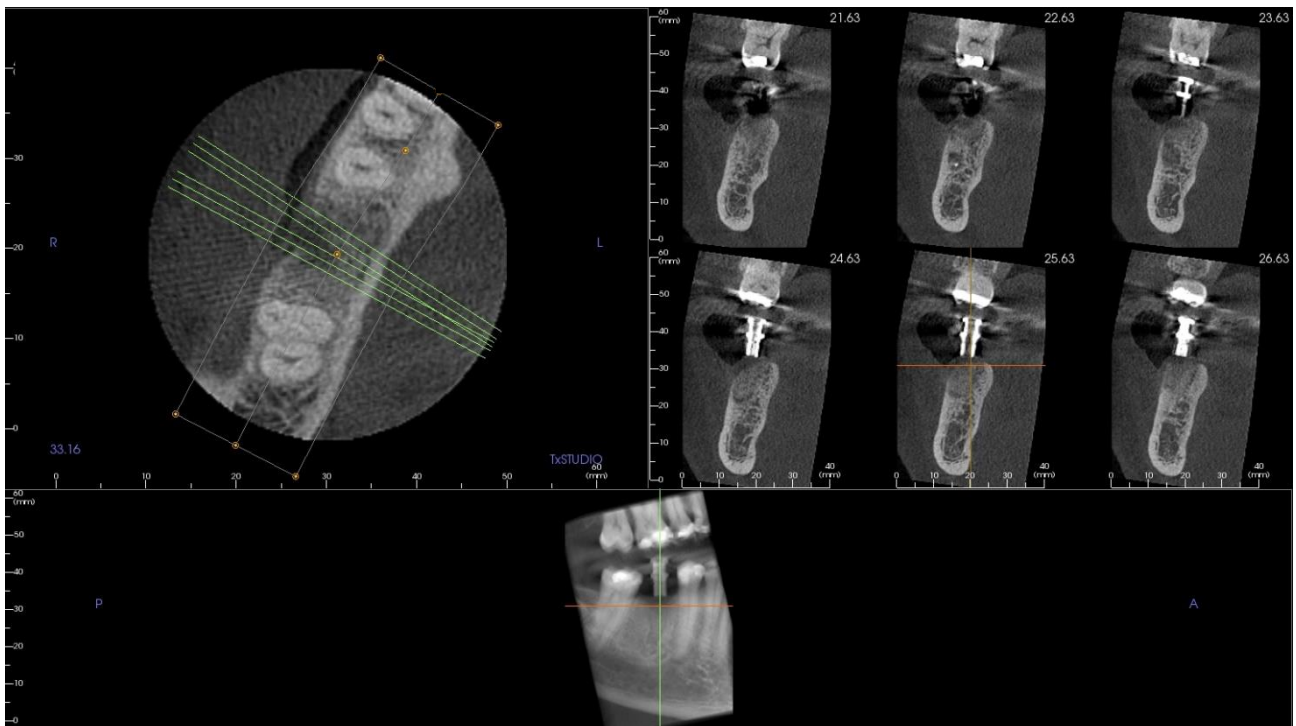
Tooth #30 is missing. A radiopaque imaging marker is noted in place. The presentation of the trabecular region is consistent with osseous augmentation surgery. The remainder of the scan is essentially unremarkable for radiographic evidence of trauma, cyst involvement, fibro-osseous lesions or tumor formation within the imaged volume of anatomy. Study should be correlated with clinical examination, medical history and patient dialogue.

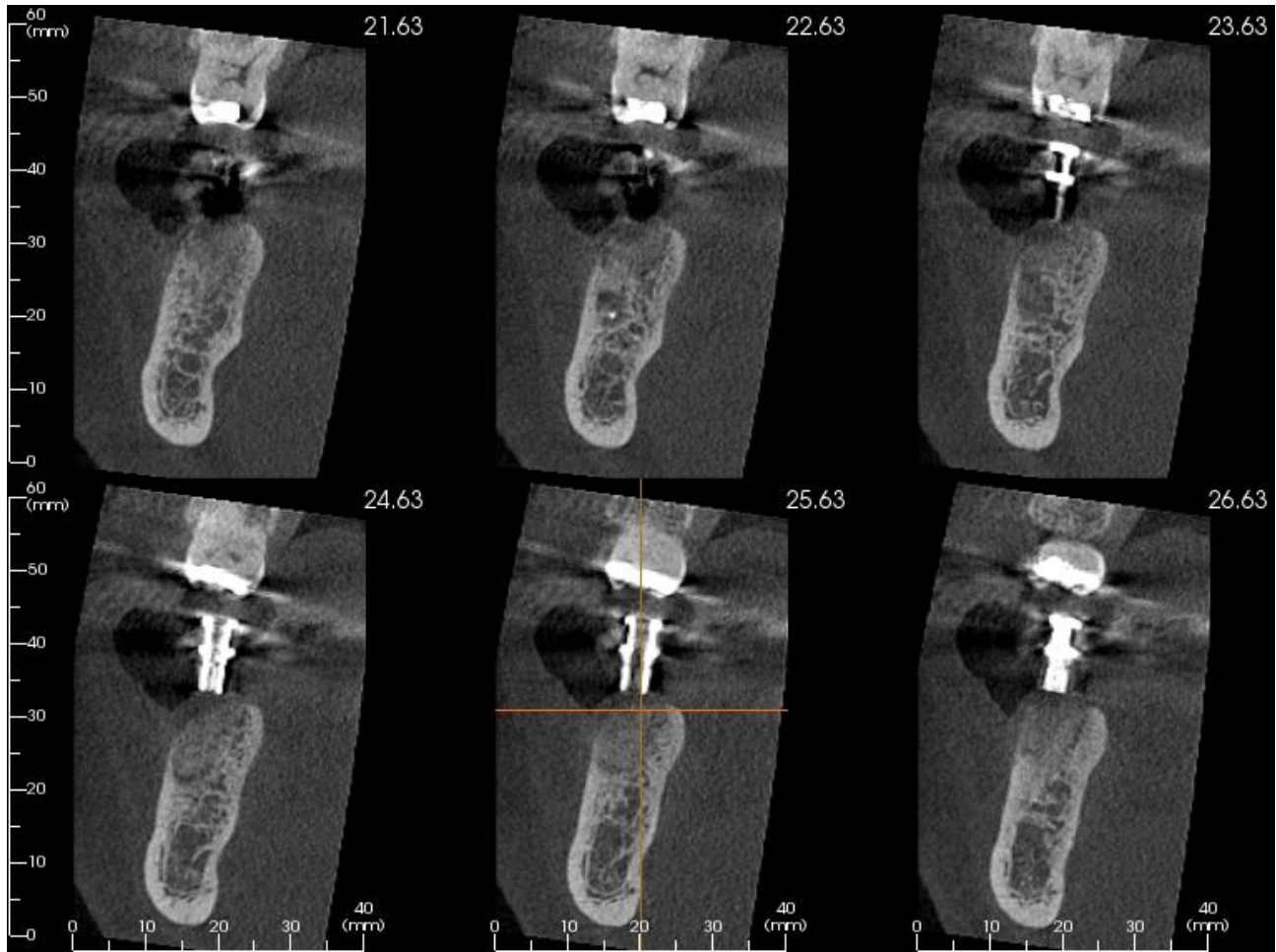
DETAILED RADIOGRAPHIC ANALYSIS: The panoramic and three-dimensionally rendered projections demonstrate a partial overview of the anatomic structures within the oral and maxillofacial complex. Tooth #30 is missing. A radiopaque imaging marker is noted in place.





The data set was evaluated in the coronal, axial and sagittal orientations. The multiplanar images depict an undistorted view of the osseous anatomy. The presentation of the trabecular region in edentulous area #30 is consistent with osseous augmentation surgery:





Please contact me directly at (312) 933-6666 or contact@MonahanRadiology.com if you have any questions. Thank you for referring to my practice.

Richard Monahan, DDS, MS, JD
Diplomate, American Board of Oral & Maxillofacial Radiology

July 33, 2018
Date of Report